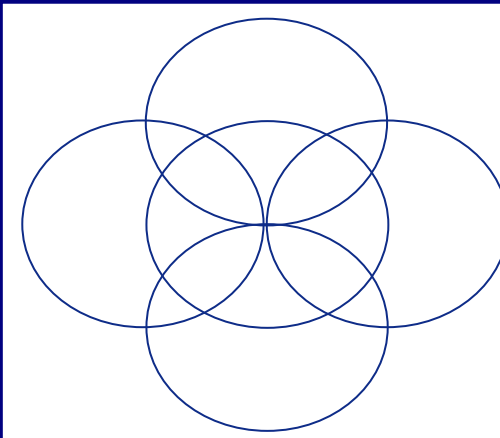

Vocal tract measurements using imaging and acoustic pharyngometry: A comparative pilot study

Erin Henigan-Douglas a, Katelyn J. Kassulke a, Reid B. Durtschi a, Shannon M.Theis a,b, Lindell R. Gentry c, and Hourri K. Vorperian a

a Waisman Center, b University of Wisconsin Medical School, c Department of Radiology
University of Wisconsin - Madison



ABSTRACT:

This study compares vocal tract (VT) measurements secured directly from imaging studies (Computed Tomography-CT) in supine body position with VT measurements secured from Acoustic Pharyngometry, or Acoustic Reflection Technology (ART), in the upright and supine body positions. ART is a noninvasive clinical tool that is used to assess the upper airway. Its use to obtain VT measurements is advantageous over imaging because it can yield higher participant inclusion compared to CT. Also, its assessment in the upright body position is typical for speech production. Preliminary data from four adult participants indicate that linear ART measurements are comparable to CT measurements, but volumetric measurements are sensitive to body position. Furthermore, findings clarify the anatomic landmark for the oral-pharyngeal junction that ART detects.

INTRODUCTION:

Vocal tract (VT) measurements are typically secured from individuals who received a radiographic study, or medical imaging studies such as Computed Tomography (CT) or Magnetic Resonance Imaging (MRI).

CT or MRI provides detailed visualization of the oral and pharyngeal regions of the VT, and have been used to secure direct measurements of the various VT structures and cavities 2, 7, 19, 20, 21.

Acoustic Pharyngometry, or Acoustic Reflection Technology (ART; by Eccovision of Hoods lab, now Sleep Group Solutions), is a non-invasive technique that uses the reflection of acoustic waveforms into the upper airway to secure an objective assessment of its length and volume 14; therefore, VT measurements are secured indirectly.

ART is used clinically to identify patients that are difficult to intubate 6, 15, assess tonsillar and adenoidal hypertrophy in children 10, detect tracheal stenosis 12, and assess sleep apnea 14. It has also been used to a limited extent in speech research relating differences in VT dimensions to changes in speech acoustics 24, 25, 26.

Although ART has been available for about two decades 9, 11, only a limited number of studies have examined the actual anatomic correlates of ART. Of those studies, only select linear ART measurements have been studied and reported to match with anatomic measurements obtained through MRI 18 and CT 3, 4.

The purpose of this pilot study is to compare VT measurements (length and volume of the oral and pharyngeal portions of the VT) secured from CT (supine body position), with VT measurements from ART in both the upright (speaking) and the supine body positions from the same participants. Because gravitational forces on the tongue and mandible affect pharyngeal cavity measurement in the supine position 8, we hypothesized supine ART measurements to be more comparable to CT (supine) measurements than to upright ART measurements.

The rationale for this study is to clarify the anatomic basis of indirect measurements of the VT that ART yields. ART is a noninvasive clinical tool that can be used to secure data available on VT measurements from more individuals, particularly atypically developing individuals (such as individuals with Down Syndrome), who are usually not referred for imaging studies due to the anticipated risk of sedation.

METHODS AND PROCEDURES:

Participants: Four adults (2 males, 2 females) participated in the current study. The two males were 52 and 29 years old, and the two females were 31 and 27 years old. Following their scheduled imaging study received for medical purposes, each participated in ART and consented to make their imaging study available for direct VT measurements purposes.

Procedures:

Acoustic Pharyngometry (ART): Each participant exhaled into the ART wave tube in the upright and supine body positions - corresponding to body positions during speaking and medical imaging studies. The five measurements ART yields include (3 length; 2 volume): 1) Vocal tract length (VTL; teeth to glottis) 2) Oral cavity length (OCL; teeth to oro-pharyngeal junction (OPJ)) 3) Pharyngeal cavity length (PCL; OPJ to glottis) 4) Oral cavity volume (OCV; teeth to OPJ) 5) Pharyngeal cavity volume (PCV; OPJ to glottis)

Next, the above measurements were made from each participant's imaging study using both 2D and 3D measurements. However, oral cavity volume was not feasible to measure from CT.

Medical imaging (MRI or CT):

The image and data acquisition methods are the same as specified in Vorperian et al. 1999, 2005.

Length measurements were taken from the 2D midsagittal slices of the individual's CT scans and measured using the software SigmaScan (by Systat).

Volumetric 3D measurements of the pharyngeal cavity (OPJ to glottis) were made from the 3D model of the pharyngeal region using the software Analyze (by AnalyzeDirect), as well as from the sum of area of axial 2D slices using SigmaScan.



Figure 1. Participants exhale into wavelube with mouthpiece for ~3 seconds in upright and supine body positions. A fraction of the acoustic wave is reflected back at each point of discontinuity in the upper airway and recorded by a microphone on the wavelube. Computer processing of the reflected sound signals provides an area distance curve representing the lumen together with cross-sectional area and volume - See figure 2.

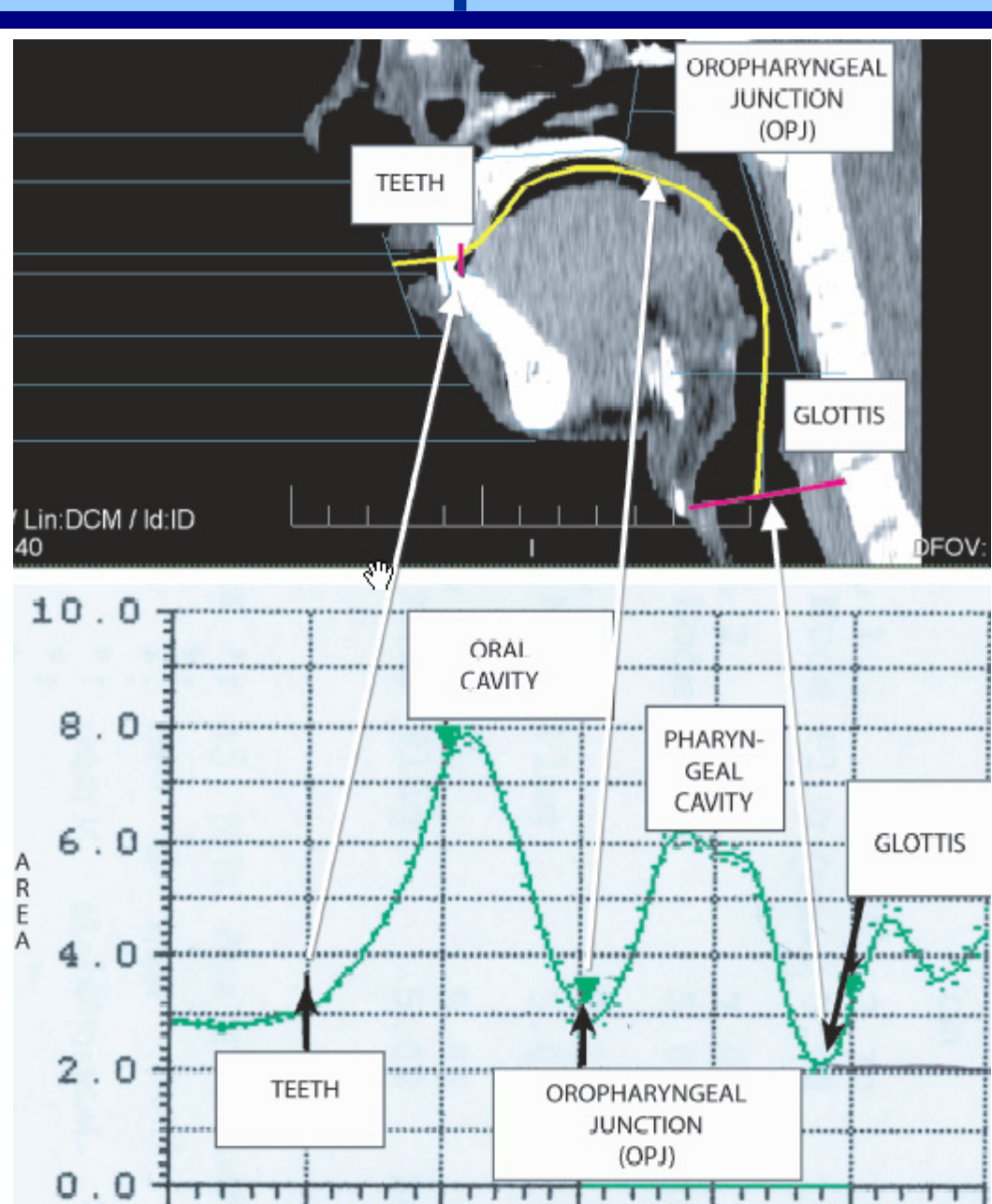


Figure 2. CT (top) and ART (bottom) equivalent anatomic landmarks from the same subject.

RESULTS:

Pilot data from the 4 participants (2 males Figures x & z; and 2 females Figures y & b) reflect the following findings:

ART Upright-Supine:

- ART length measurements of VT length (VTL), oral cavity length (OCL), and pharyngeal cavity length (PCL) were comparable in the upright and supine body positions.
ART pharyngeal cavity volume (PCV) was consistently smaller in the supine position.

CT vs ART:

- Length measurements were comparable between CT versus ART for VT length (VTL), oral cavity length (OCL), and pharyngeal cavity length (PCL), in both body positions.
The pharyngeal cavity volume measurements were more comparable between CT and ART-supine (PCV-supine) than CT and ART-upright (PCV-upright). This body position effect is expected given the gravitational pull in the supine position on the soft tissues in the pharyngeal region that have been documented to decrease pharyngeal cavity.
The pharyngeal cavity volume measurements from ART-supine (PCV-supine) were consistently larger than pharyngeal volume measurements from CT (using both 3D volume via Analyze, and 2D SigmaScan area functions).
Based on comparison of volumetric measurements of ART-PCV-supine and CT (3D), the anatomic correlate that ART detects for the oro-pharyngeal junction appears to be at the level of the ANS-PNS plane. Cross sectional area comparisons between those two techniques support this general conclusion.

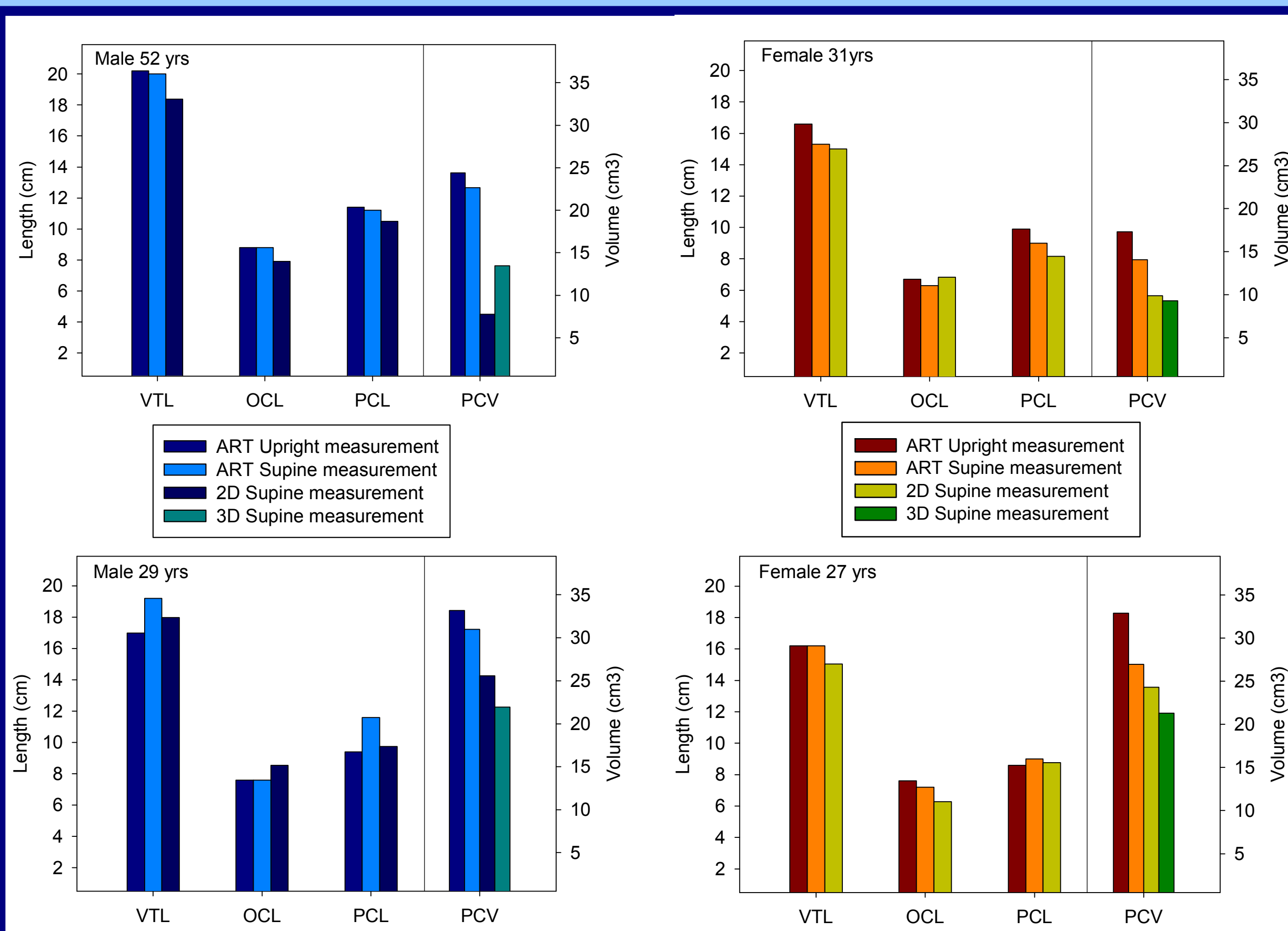


Figure 3. Upright and Supine measurements for two adult males and two adult females are shown for Vocal Tract Length (VTL), Oral Cavity Length (OCL), Posterior Cavity Length (PCL), and Posterior Cavity Volume (PCV). Length (cm) measurements were gathered using ART and 2D imaging, while volumetric (cm^3) measurements were gathered using ART, 2D and 3D imaging.

MAJOR CONCLUSIONS:

- Overall, results indicate similarities between VT measurements taken from CT and ART in the supine body position.
- ART length measurements (VTL, OCL & PCL) are not altered by body position.
- Volumetric measurements of the pharynx are sensitive to body position. Specifically, volumetric measurements are consistently smaller in the supine position. This is to be expected given the gravitational pull on soft tissue structures in the supine body position 8, 16.
- The larger pharyngeal volume from ART compared to CT could be due to possible airflow entering the nasal cavity, thus resulting in an inflated volume. Alternatively, it could be due to ART capturing an overall volume without as much sensitivity as CT measurements in depicting the volumetric measurements in the hypopharyngeal region, including the region of the piriform sinuses and the valleculae.
- ART is a non-invasive and a relatively inexpensive clinical and research tool that can be used to gather VT measurement from many individuals, including young individuals (ages four and up) and atypically developing individuals who will not be imaged or cannot be imaged due to medical concerns.
- ART as a research tool can be useful to increase knowledge on the development of the upper airway in typically and atypically developing individuals.
- Developmental ART data in upright position, ideally in conjunction with acoustic analysis, can be useful in establishing sex specific anatomic-acoustic correlates for speech 23. This in turn can serve as a knowledge basis for clinical use in speech intervention.
- ART is a useful clinical tool that, as noted earlier, has been used medically to assess patients that are difficult to intubate 6, 15, assess tonsillar and adenoidal hypertrophy in children 10, detect tracheal stenosis 12, and assess sleep apnea 14. ART can also be a useful clinical tool for Speech-Language Pathologists. Specifically, ART can be used to access the patency of the upper airway; measure the changes in the oral and pharyngeal cavities pre and post surgical management for craniofacial anomalies patients; gather information about the oral and pharyngeal cavities in a non-invasive manner; make predictions regarding changes in oral and pharyngeal regions of the VT to changes in speech acoustics and vowel acoustic space 22; and could potentially help understand the role anatomy plays in speech intelligibility.

ACKNOWLEDGMENTS:

This work was supported by NIH/NIDCD grant # R01-DC 006282. Also, a core grant to the Waisman Center from NIH-NICHD P30-HD03352. Special thanks to Carlyn A. Burris, Abby M. Mohoney, & Eric E. Schafer for assistance with poster preparation.

SELECT REFERENCES:

1. AnalyzeDirect, Inc. Available at http://www.analyzedirect.com/. Retrieved June 27, 2007.
2. Arens R, McDonough J, Corbin A. Linear dimensions of the upper airway structure during development: Assessment by magnetic resonance imaging. American Journal of Respiratory and Critical Care Medicine. 2002; 165:117-122.
3. D'Urzo AD, Lawson VG, Vassal KP, Rebuck AS, Slutsky AS, Hoffstein V. Airway area by acoustic response measurements and computerized tomography. American Review of Respiratory Disease. 1987;135:392-395.
4. D'Urzo AD, Rubinstein I, Lawson VG. Comparison of glottic areas measured by acoustic reflections vs. computerized tomography. Journal of Applied Physiology. 1988;64:367-370.
5. Eccovision Acoustic Diagnostic Imaging. Hood Laboratories. Acoustic Pharyngometer Operator Manual; 2004;1:26.
6. Eckmann DM, Giassenberg R, Gavriely N. Acoustic reflectometry and endotracheal intubation. Anesthesia and Analgesia 1996; 83:1084-1089.
7. Fitch WT, Giedd J. Morphology and development of the human vocal tract: A study using magnetic resonance imaging. Journal of the Acoustical Society of America. 1999;106:1511-1522.
8. Fouke JM, Strohl, KF. Effect of position and lung volume on upper airway geometry. Journal of Applied Physiology. 1987 63(1), 375-80.
9. Fredberg JJ, Worth ME, Glass GM, Dorkin HL. Airway area by acoustic reflections measured at the mouth. Journal of Applied Physiology. 1980;48:749-58.
10. Hatzakis G, Karan N, Cook J, Schloss M, Davis G. Acoustic reflectance of pharyngeal structures in children. International Journal of Pediatric Otorhinolaryngology. 2003;373-381.
11. Hoffstein V, Fredberg JJ. The acoustic reflection technique for non-invasive assessment of upper airway area. [Review] European Respiratory Journal. 1991;4:602-611.
12. Hoffstein V, Zamel N. Tracheal stenosis measured by the acoustic reflection technique. The American Review of Respiratory Disease. 1984; 130:472-475.
13. Kent RD, Pagan-Neves L, Hustad KC. Children's Speech Sound Disorders: An Acoustic Perspective. In Children's speech disorders: An acoustic perspective. 2008 in press.
14. Marshall I, Rogers M, Drummond G. Acoustic reflectometry for airway measurement. Principles, limitations and previous work. Clinical Physics and Physiological Measurement. 1991; 12:131-141.
15. Ochroch AE, Eckmann DM. Clinical Application of Acoustic Reflectometry in Predicting the Difficult Airway. Anesthesia and Analgesia. 2002; 95:645-649.
16. Stone, M, Stock, G, Bunin, K, Kumar, K, Epstein, M, Kambhampettu, C, Li, M, Parthasarathy, V, & Prince, J. Comparison of speech production in upright and supine position. The Journal of the Acoustical Society of America. 2007; 122, 532-541.
17. Systat, Inc. Available at http://www.systat.com/products/SigmaScan/ Retrieved on Nov 3, 2008
18. Tameem HZ, Mehta BV. Solid Modeling of Human Vocal Tract using Magnetic Resonance Imaging and Acoustic Pharyngometer. Conference Proceedings of the IEEE Engineering in Medicine and Biology Society. 2004;7:5115-5118.
19. Uong EC, McDonough M, Tayag-Kier CE, Zhao H, Haselgrove J, Soroush M, Schwab RJ, Pack AI, Arens R. Magnetic Resonance Imaging of the Upper Airway in Children with Down syndrome. American Journal of Respiratory and Critical Care Medicine. 2001;163:731-736.
20. Vorperian HK, Kent RD, Gentry LR, Yandell BS. Magnetic Resonance Imaging Procedures to Study the Concurrent Anatomic Development of the Vocal Tract Structures: Preliminary Results. International Journal of Pediatric Otorhinolaryngology. 1999; 49:197-206.
21. Vorperian HK, Kent RD, Lindstrom MJ, Kalina CM, Gentry LR, Yandell BS. Development of Vocal Tract Length during Early Childhood: A Magnetic Resonance Imaging Study. The Journal of the Acoustical Society of America. 2005; 117:338-350.
22. Vorperian HK, Kent R. Vowel Acoustic Space Development in Children: A Synthesis of Acoustic and Anatomic Data. Journal of Speech, Language and Hearing Research. 2007; 50:1510-1545.
23. Vorperian HK, Schmek ME, Wang S, Chung M, Kent R, Durtschi R, Ziegler AJ, Gentry LR. Anatomic Development of the Vocal Tract during the First Two Decades of Life: Evidence on Prepubertal Sexual Dimorphism from MRI and CT Studies. Poster Presented at the meeting of the Acoustical Society of America, New Orleans, LA, 2007.
24. Xue SA, Hao GJ. Changes in the Human Vocal Tract due to Aging and the Acoustic Correlates of Speech Production: A Pilot Study. Journal of Speech, Language and Hearing Research. 2003; 46:689-701.
25. Xue SA, Hao GJ. Mayo R. Volumetric Measurements of Vocal Tracts for Male Speakers from Different Races. Clinical Linguistics and Phonetics. 2006; 20:691-702.
26. Xue SA, Hao GJ. Normative Standards for Vocal Tract Dimensions by Race as Measured by Acoustic Pharyngometry. Journal of Voice. 2006; 20:391-400.