

Anatomic measurement accuracy: CT parameters and 3D rendering effects

Brian J Whyms ^a, E Michael Schimek ^a, Hourii K Vorperian ^a,
Lindell R Gentry ^b, and Edward T Bersu ^c

University of Wisconsin-Madison

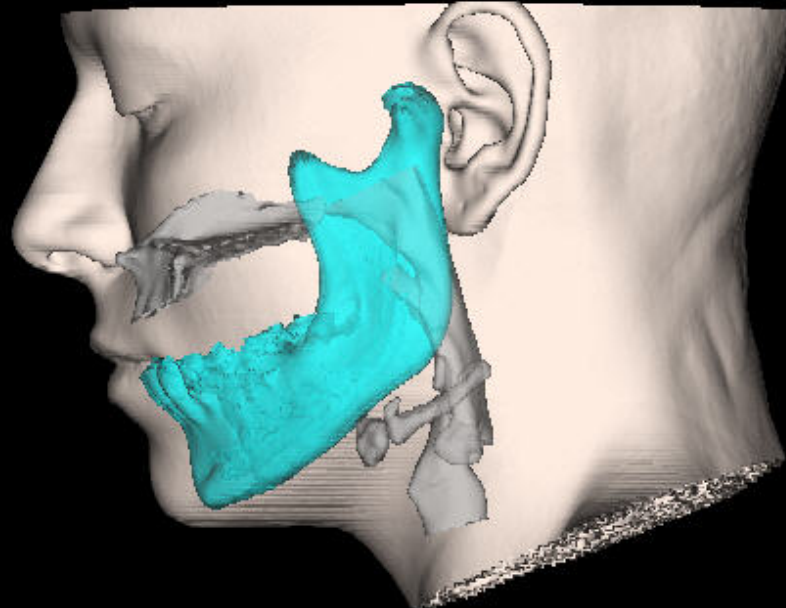
^a Waisman Center, Vocal Tract Development Lab

^b UW Hospital and Clinics, Radiology Department

^c Department of Neuroscience

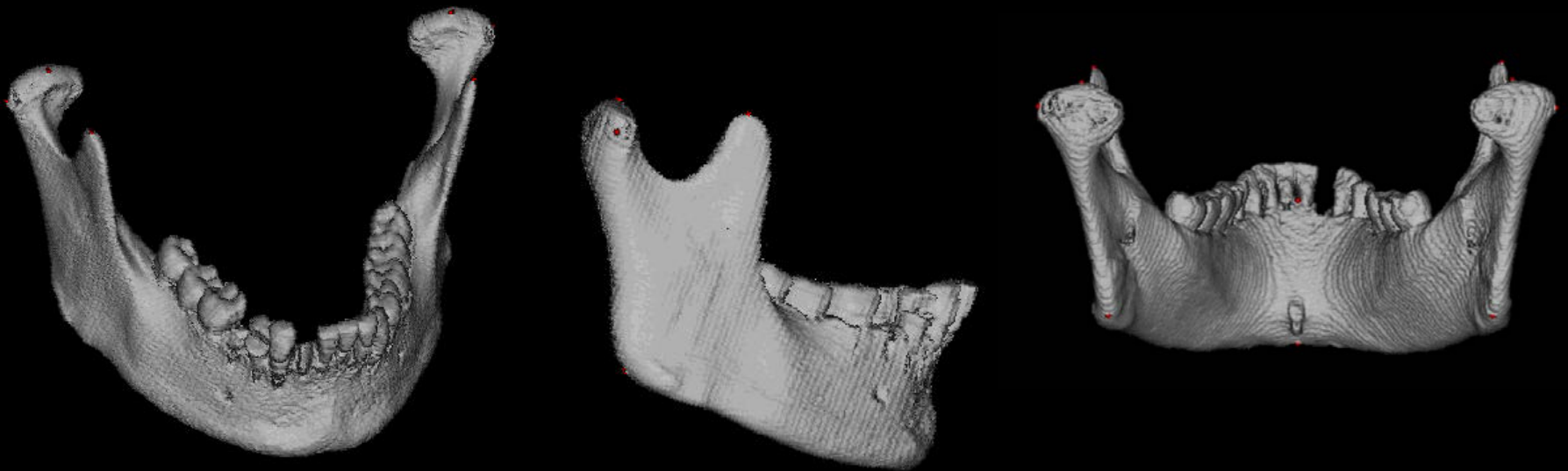
INTRODUCTION

- Measurements from 3D-CT rendering are used in research and clinical management (treatment planning, patient monitoring, oncology, and diagnostic aid/efficiency)
- Measurement accuracy has been documented for linear measurements, but not volume or surface area
- How do image acquisition parameters affect measurements?



Purpose:

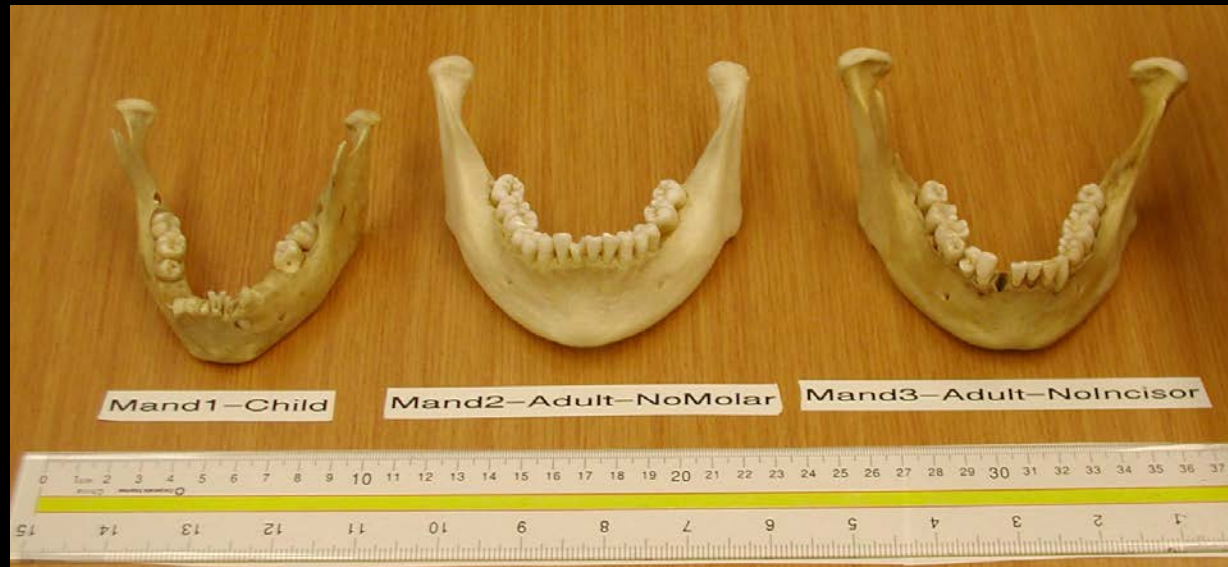
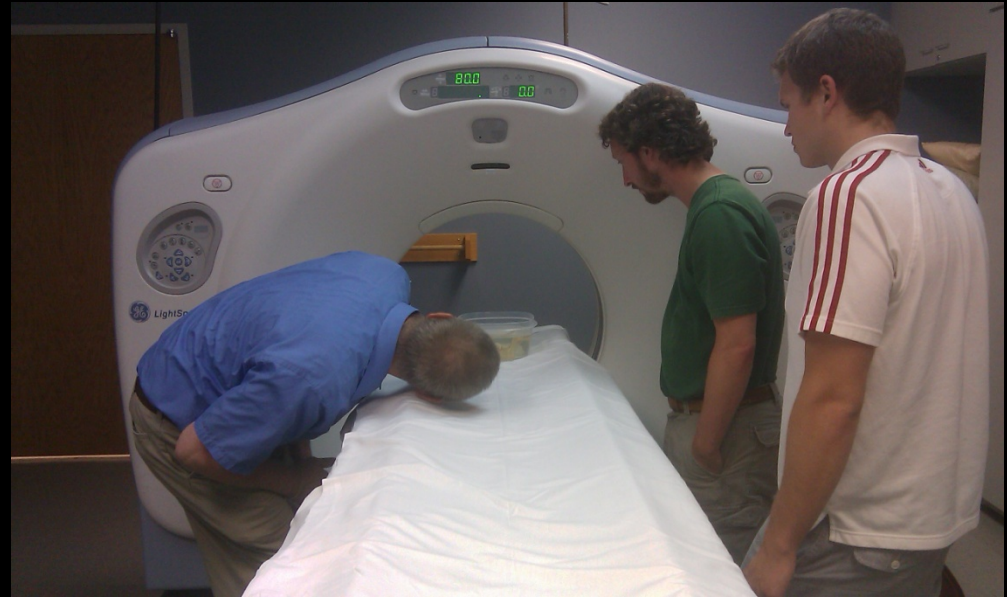
- Confirm linear measurement accuracy
- Investigate accuracy of volume and surface area
- Assess effect of 3D-CT image resolution on measurements
- Evaluate effect of 3D-CT rendering techniques on measurements



METHODS

Scanned:

- 3 human mandibles
- a phantom object



Phantom Object Prism

Independent Variables:

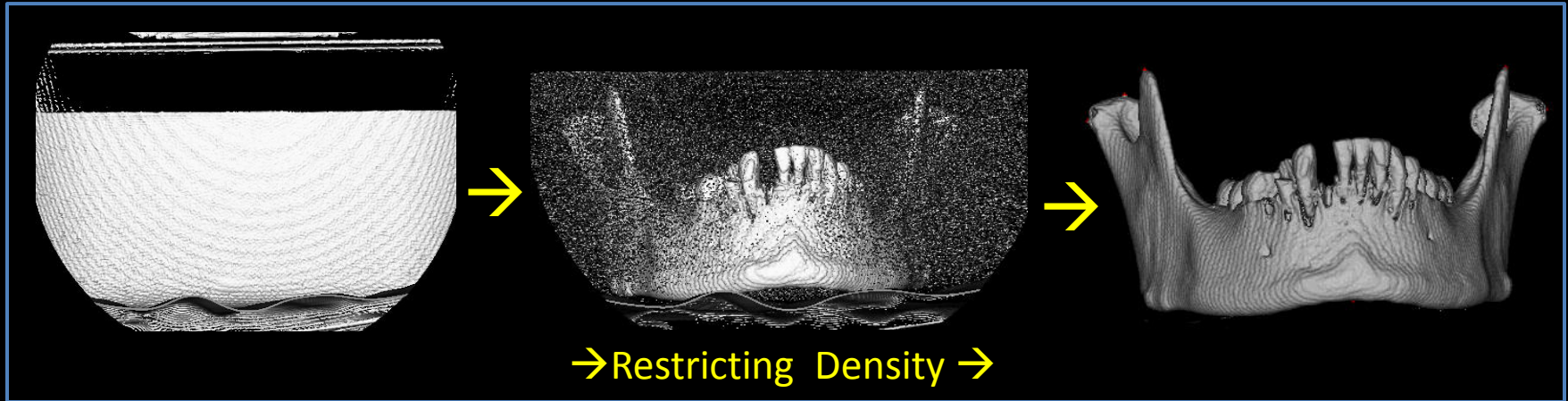
CT Scanner Parameters:

1. Reconstruction Algorithm (Boneplus, Soft, Standard)
2. Slice Thickness (1.25mm, 2.5mm)
3. FOV (16x16cm, 18x18cm, 29.9x29.9cm)

3D Rendering Techniques: (Next Slide)

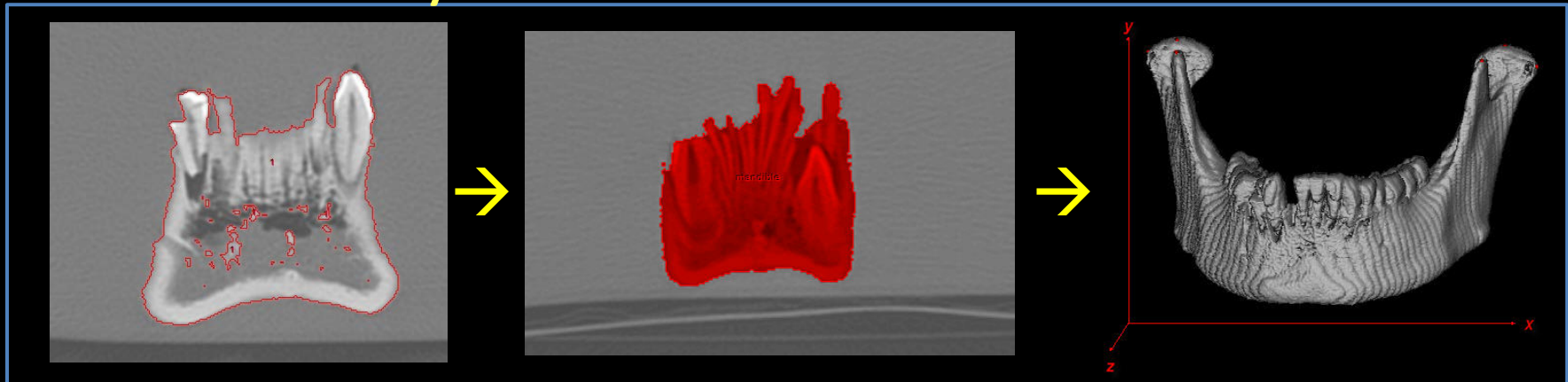
3D Rendering Techniques:

1. Volume Render

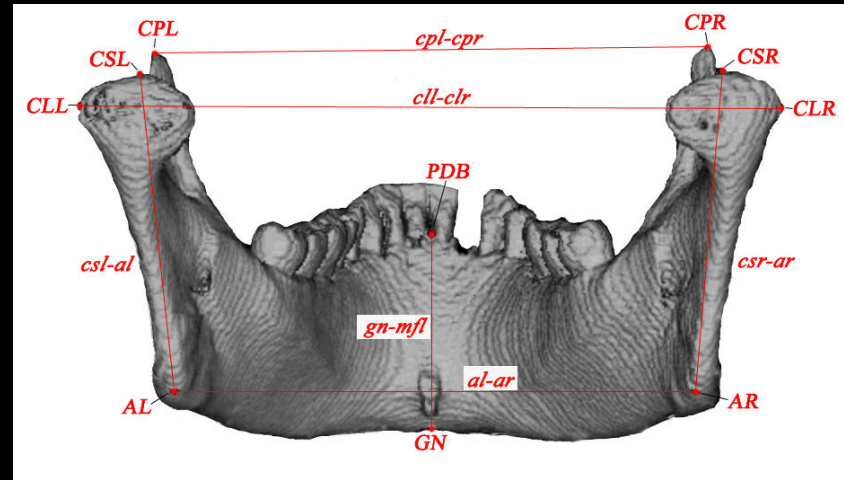
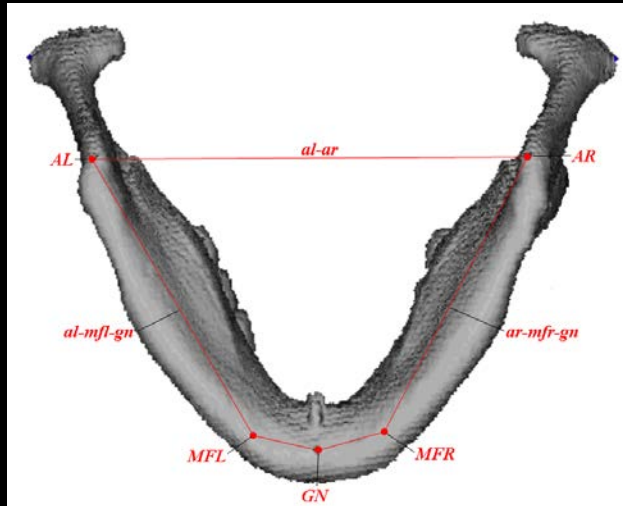


Surface-Shaded Display:

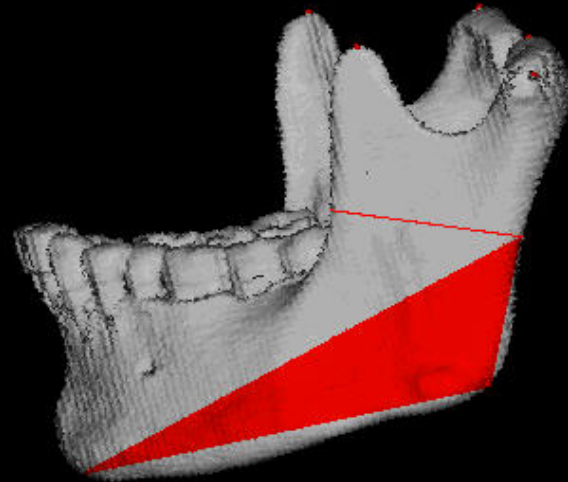
2. Automatically Segmented &
3. Manually Defined



- **Linear Measurements** (8 linear, 2 angular) were based on landmarks common to published literature



- **Volume** & **Regional Surface Area Measurements**

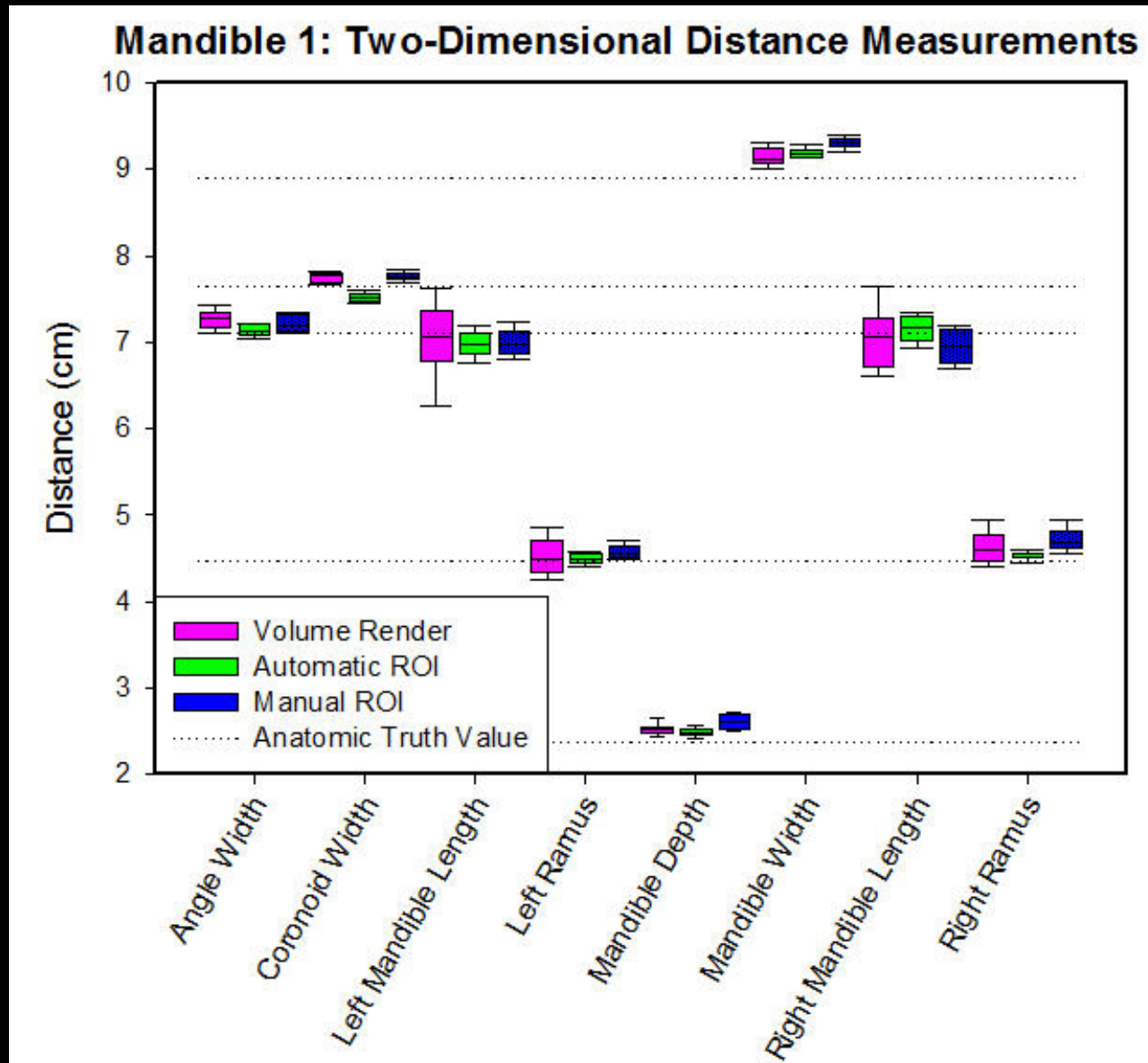


- **Measurements: Computer models vs. Anatomic Truth**

RESULTS:

1. Linear
2. Volume
3. Surface Area

RESULTS: Linear Measurements



RESULTS: Linear Measurements

Linear Measurements

Object	Rendering Technique	Acceptable	Reconstruction Alg.	Acceptable	Field of View (cm)	Acceptable	Slice Thickness (mm)	Acceptable
Mandibles	VR	•	Bone	•	16x16	•	1.25	•
	Auto ROI	•	Soft	•	18x18	•	2.5	•
	Manual ROI	•	Standard	•	29.9x29.9	•		
Phantom Object	VR	•	Bone	•	16x16	•	0.625	•
	Auto ROI	•			18x18	•	1.25	•
	Manual ROI	•	Standard	•	29.9x29.9	•	2.5	•

• Denotes a group of "acceptable" measurements satisfying $ARE \leq 0.05$

- ✓ Linear measurements from 3D-CT are accurate
- ✓ Linear accuracy is **not** sensitive to the CT scanning parameters or rendering techniques

RESULTS: Volume Measurements

Volume Measurements									
Object	Rendering Technique	Acceptable	Reconstruction Alg.	Acceptable	Field of View (cm)	Acceptable	Slice Thickness (mm)	Acceptable	
Mandibles	VR		Bone		16x16		1.25		•
	Auto ROI		Soft		18x18		2.5		
	Manual ROI		Standard		29.9x29.9				
Phantom Object	VR	•	Bone	•	16x16	•	0.625		•
	Auto ROI				18x18	•	1.25		•
	Manual ROI	•	Standard	•	29.9x29.9	•	2.5		•

• Denotes a group of "acceptable" measurements satisfying $ARE \leq 0.05$

- Only 1.25mm Slice Thickness for the Mandibles produced accurate group of volumes
- HOWEVER, all but one of the phantom object parameters produced accurate volumes
- Therefore, we looked further into the effect of slice thickness

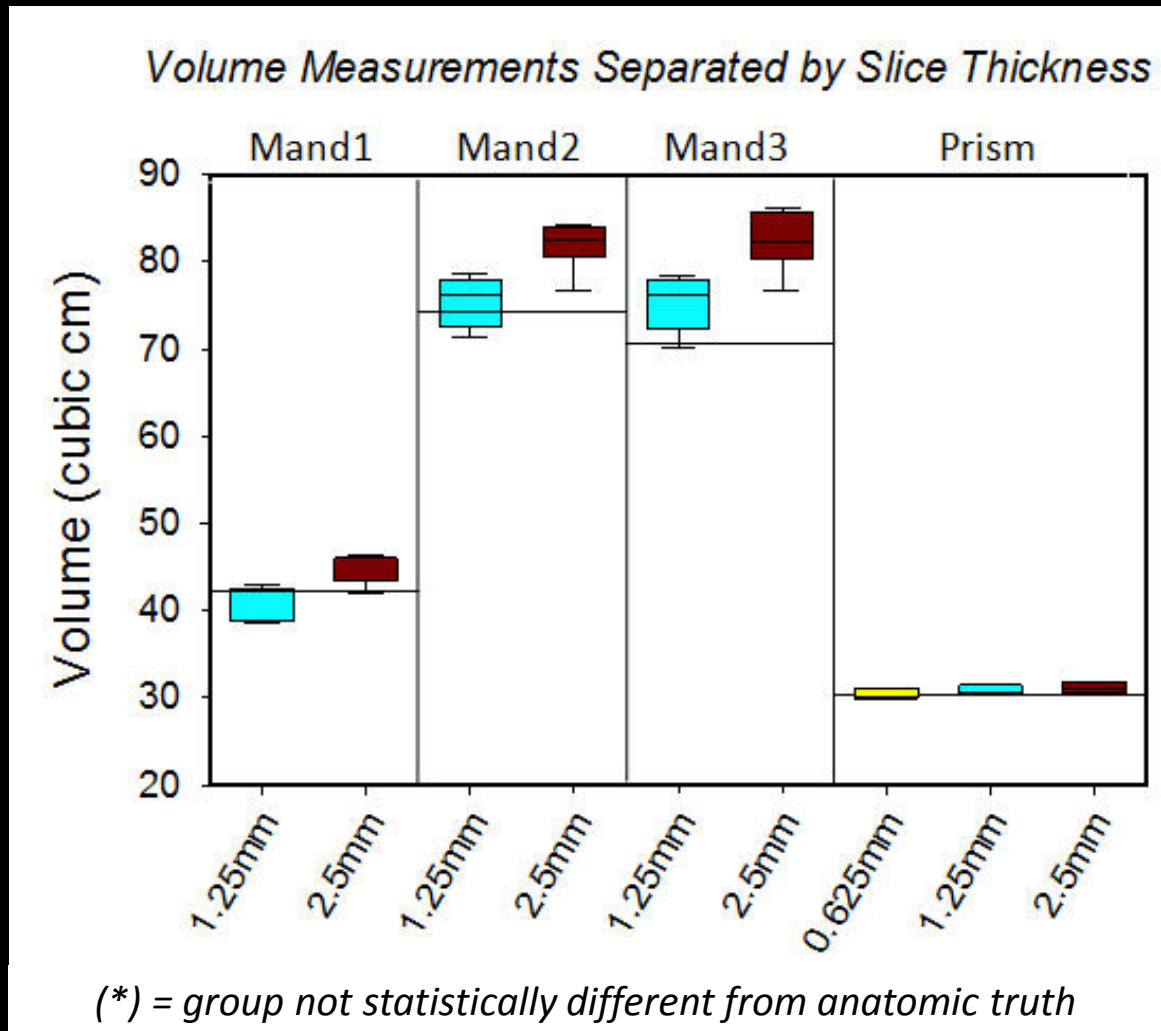
RESULTS: Volume Measurements

Mandible Volumes Separated by Slice Thickness						
Object	Rendering Technique	Acceptable	Reconstruction Algorithm	Acceptable	Field of View (cm)	Acceptable
1.25mm	VR	•	Bone	•	16x16	
	Auto ROI	•	Soft		18x18	•
	Manual ROI	•	Standard	•	29.9x29.9	•
2.5mm	VR		Bone		16x16	
	Auto ROI				18x18	
	Manual ROI		Standard		29.9x29.9	

• Denotes a group of "acceptable" measurements satisfying $ARE \leq 0.05$

1. Models from 1.25mm original data = (7/9) groups within 0.05 ARE and remaining two approach threshold.
2. Models of 2.5mm slice thickness = NO groups achieve 0.05 ARE.

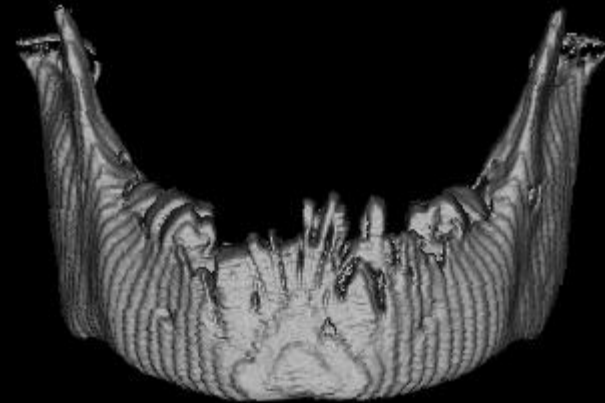
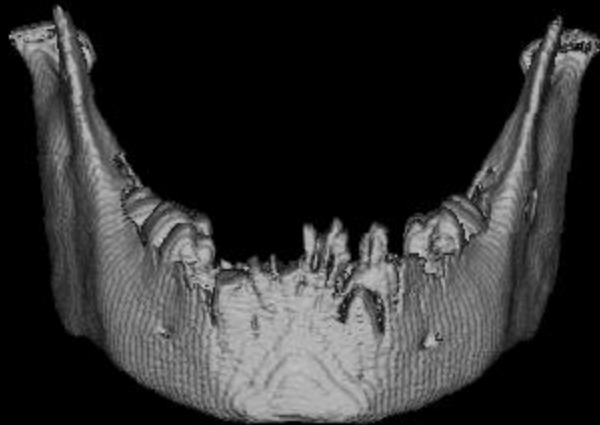
RESULTS: Volume Measurements



Increase slice thickness = groups of measurements stray farther from anatomic truth

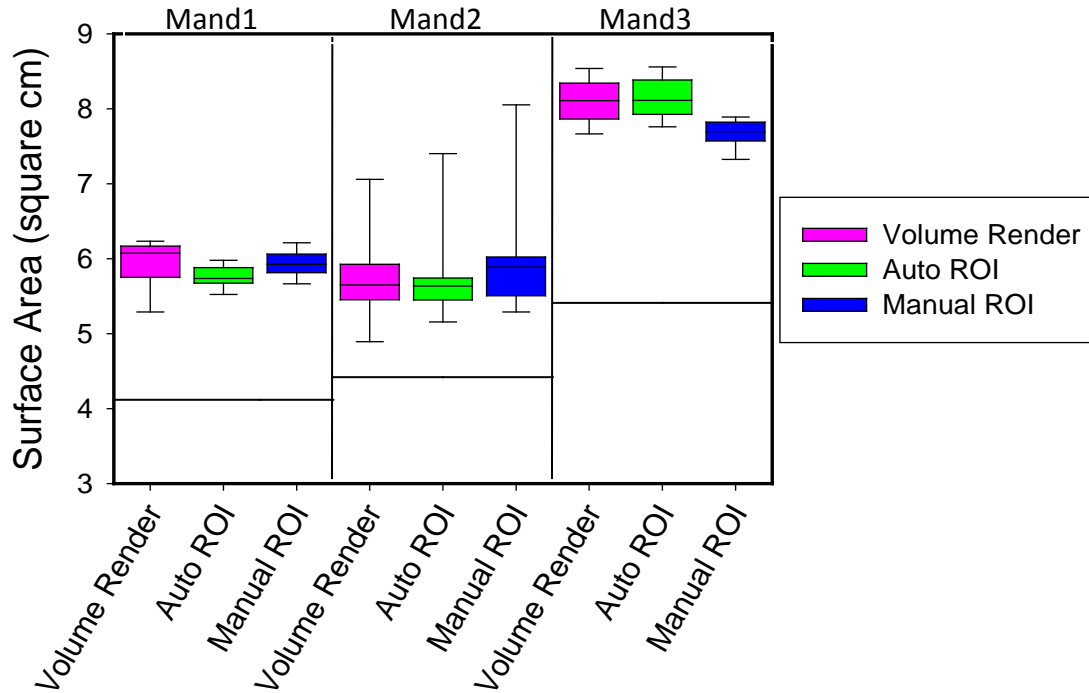
To Summarize:

- ✓ Volume measurement accuracy is optimal from thin slices (1.25mm)
- ✓ Volume measurements from thin slices are **not sensitive** to CT scanning parameters or 3D rendering techniques



THIN (1.25mm) vs. *THICK (2.5mm)*

Surface Area Measurements Separated by Rendering Mode Algorithm



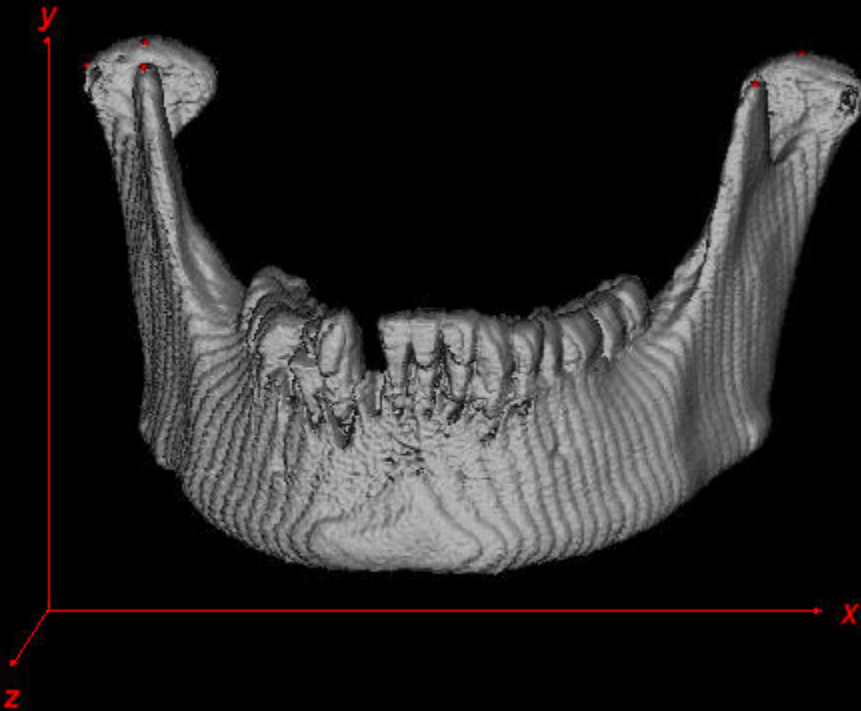
Surface Area Measurements

Object	Rendering Technique	Acceptable	Reconstruction Alg.	Acceptable	Field of View (cm)	Acceptable	Slice Thickness (mm)	Acceptable
Mandibles	VR		Bone		16x16		1.25	
	Auto ROI		Soft		18x18		2.5	
	Manual ROI		Standard		29.9x29.9			
Phantom Object	VR		Bone		16x16		0.625	
	Auto ROI				18x18		1.25	
	Manual ROI		Standard	•	29.9x29.9		2.5	

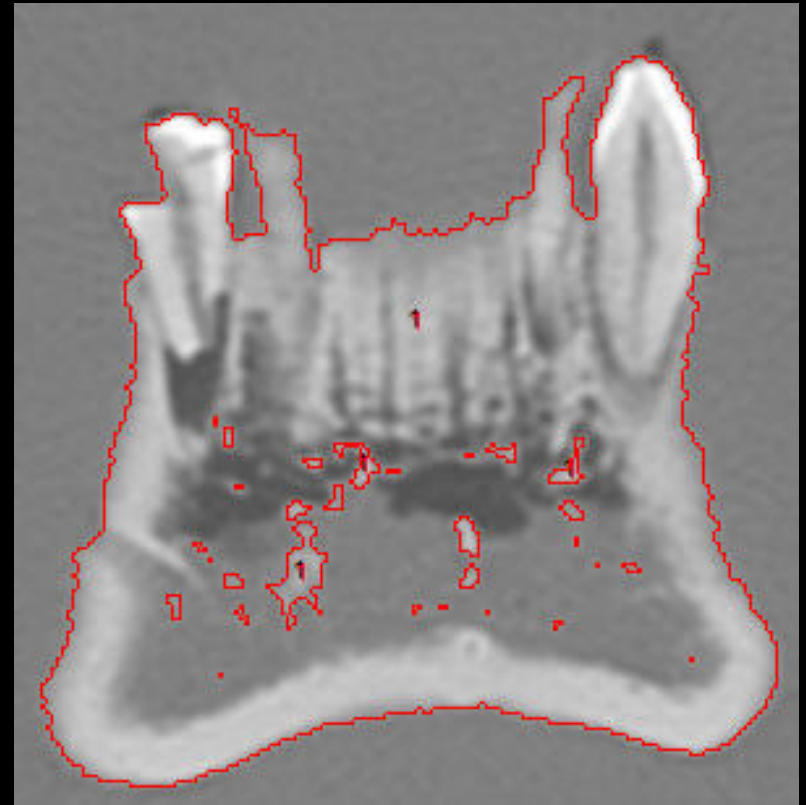
• Denotes a group of "acceptable" measurements satisfying $ARE \leq 0.05$. **Standard Reconstruction Kernel for Phantom Object = large SD**

- ✓ Surface area measurements are ***not*** accurate
 - All measurements were 25-45% inflated

Volume Render = Slice Summation



Surface ROI = Stair-Stepping



CONCLUSIONS

1. Linear Measurements: *ACCURATE*

- NOT sensitive to scanning parameters or rendering techniques

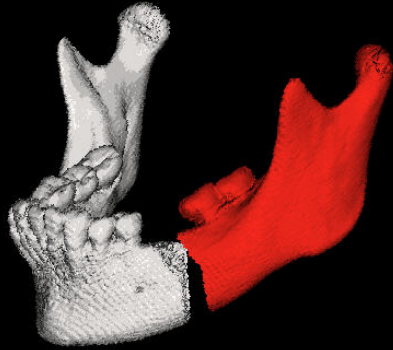2. Volume : *THIN* slices *MOST ACCURATE*

- NOT sensitive to scanning parameters or rendering techniques

3. Surface Area: *NOT ACCURATE*

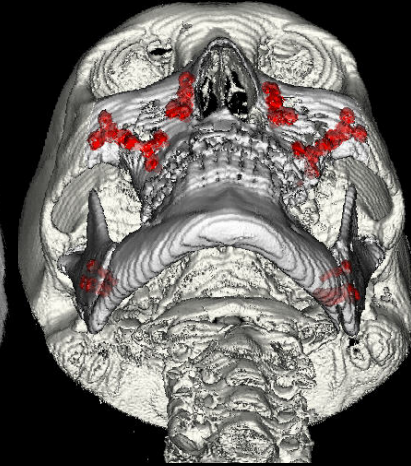
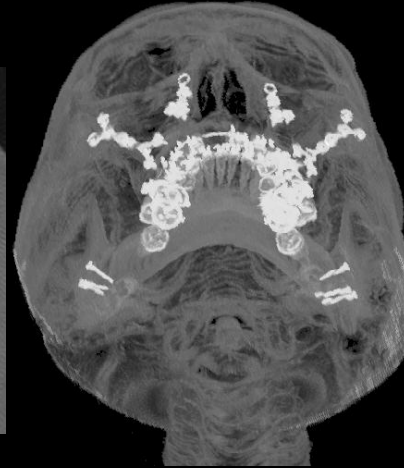
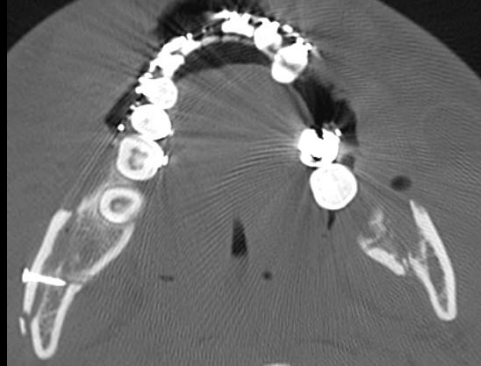
- Inflated Measurements

Potential applications :



→ Characterization and grading of **bone fractures**

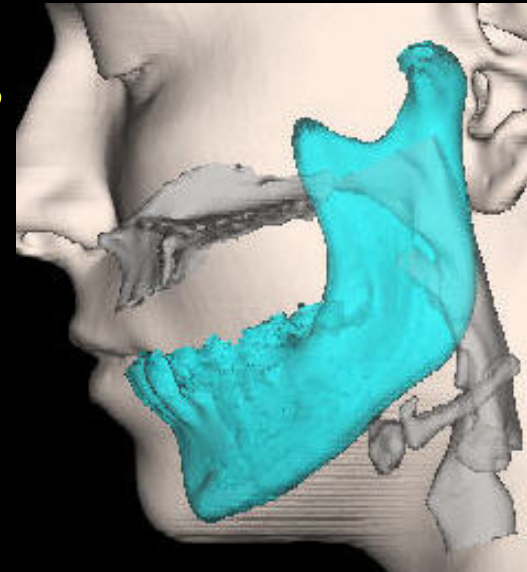
**Orthopedic treatment
and Surgical implants** →



→ 3D-CT alongside 2D images helps increase rate of successful diagnoses

✓ Vocal Tract Development Lab subject scans
can be used for researching:

- **Speech production**
- **Biological basis of development**
- **Developmental Disorders**

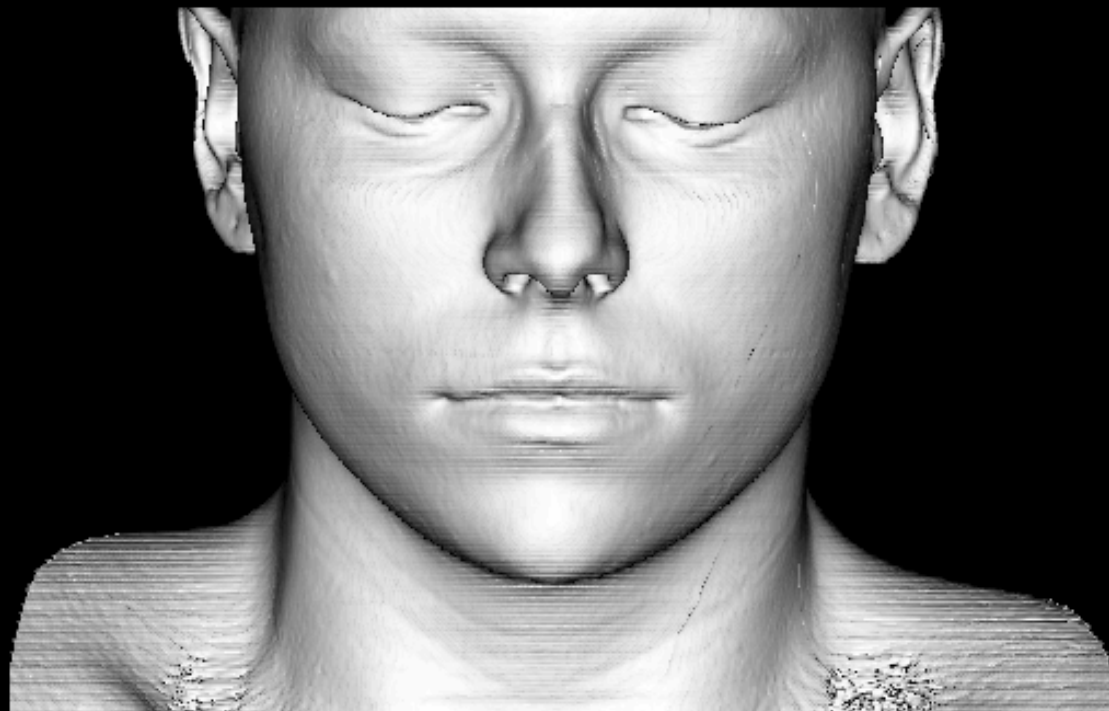


References:

1. Guitton, T. G., H. J. van der Werf, et al. (2010). "Quantitative three-dimensional computed tomography measurement of radial head fractures." J Shoulder Elbow Surg 19(7): 973-977.
2. Ravenel, J. G., W. M. Leue, et al. (2008). "Pulmonary nodule volume: effects of reconstruction parameters on automated measurements--a phantom study." Radiology 247(2): 400-408.
3. Ball, G., D. Woodside, et al. (2011). "Relationship between cervical vertebral maturation and mandibular growth." Am J Orthod Dentofacial Orthop 139(5): e455-461.
4. El-Zanaty, H. M., A. R. El-Beialy, et al. (2010). "Three-dimensional dental measurements: An alternative to plaster models." Am J Orthod Dentofacial Orthop 137(2): 259-265.
5. Alkadhi, H., S. Wildermuth, et al. (2004). "Accuracy and time efficiency for the detection of thoracic cage fractures: volume rendering compared with transverse computed tomography images." J Comput Assist Tomogr 28(3): 378-385.
6. Ringl, H., R. Schernthaner, et al. (2009). "Three-dimensional fracture visualisation of multidetector CT of the skull base in trauma patients: comparison of three reconstruction algorithms." Eur Radiol 19(10): 2416-2424.

QUESTIONS?

Process of Volume Render Segmentation:



Acknowledgements

This work was supported by
National Institute on Deafness and Other Communication Disorders

NIH-NIDCD Grant R01 DC6282

(MRI and CT Studies of the Developing Vocal Tract)